



Contents lists available at ScienceDirect

Gynecology and Minimally Invasive Therapy

journal homepage: www.e-gmit.com

Case report

Laparoscopic retrieval of a foreign body (broken surgical knife) from retroperitoneal space: An interesting case

Dipak Limbachia ^a, Preeti Gandhi ^{b, *}^a Advanced Endoscopy and Oncology Centre, EVA Women's Hospital, Ahmedabad, Gujarat, India^b Department of Gynaecology, Scunthorpe General Hospital, Northern Lincolnshire and Goole Hospitals NHS Foundation Trust, United Kingdom

ARTICLE INFO

Article history:

Received 24 July 2016

Received in revised form

7 October 2016

Accepted 26 October 2016

Available online xxx

Keywords:

broken knife

foreign body

laparoscopy

retroperitoneal

ABSTRACT

We present a rare and interesting case, of a retrieval of a broken surgical knife blade, from the retroperitoneal space, through laparoscopic approach by a gynecology endoscopist. A 40-year-old man underwent open lumbar discectomy surgery, when the surgical knife blade inadvertently broke, and was retained in the disc space. The broken blade could not be removed during the initial surgery. A second attempt was made to retrieve it; however, it migrated further anteriorly into the retroperitoneal space. Subsequently, a gynecology endoscopist was called in, who successfully retrieved the broken blade from the retroperitoneal space through laparoscopic approach. A four-port laparoscopic transperitoneal approach was performed. The broken fragment of the knife was found just medial to the left common iliac artery in the retroperitoneal space, which was removed. Operation time was 40 minutes and the postoperative course was uneventful.

Copyright © 2017, The Asia-Pacific Association for Gynecologic Endoscopy and Minimally Invasive Therapy. Published by Elsevier Taiwan LLC. This is an open access article under the CC BY-NC-ND license (<http://creativecommons.org/licenses/by-nc-nd/4.0/>).

Introduction

We present a case of a retrieval of a broken surgical knife blade, from the retroperitoneal space, through laparoscopic approach by a gynecology endoscopist. Approval from the Institutional Review Board was not undertaken as it is not the part of clinical trial; it is the retrospective analysis of our clinical work.

Case Report

A 40-year-old man underwent a hemi-laminectomy for lumbar disc herniation at the L5-S1 level. While retracting the cord and incising the intervertebral disc, the distal fragment of the number 15 surgical knife broke, and migrated into the intervertebral disc space.

Despite the best efforts of the orthopedic surgeon, the knife fragment could not be retrieved and it migrated further anteriorly. A neurosurgeon was contacted, and a second surgery was planned

couple of days later to retrieve the broken knife fragment. Joint procedure along with the neurosurgeon was also unsuccessful in removing the foreign body; it slipped further anteriorly. An urgent computed tomography scan was arranged, which revealed the broken blade (Figure 1) to be situated considerably anterior in the retroperitoneal space at the L5-S1 level. The orthopedic surgeon discussed this case with gynecology endoscopist who decided on a laparoscopic approach to retrieve the fragment.

Four-port laparoscopy was performed with a 12-mm supra-umbilical port, two 5-mm ports in the left iliac fossa, and one 5-mm port in right iliac fossa. During laparoscopy, systematic steps were followed as shown in Video 1. The peritoneum over the sacral promontory was opened and the presacral space (*holy plane*) was dissected. Dissection continued over left common iliac artery. A hematoma was evident, just medial to the left common iliac artery, suggesting the possible location of the knife. Blunt dissection continued in and around the hematoma site using a bipolar and Maryland grasper, and the tip of the broken knife fragment just became visible as seen in Video 1. Further dissection was carried out over the external iliac artery, external iliac vein, and internal iliac artery, to expose these vessels prior to any attempt at removal of the knife. This precaution was taken to deal with an accidental hemorrhage if encountered while removing the knife fragment. The assistant from the right side grasped the broken fragment of the

Conflicts of interest: The authors have no conflicts of interest to report.

* Corresponding author. Department of Gynaecology, Scunthorpe General Hospital, Northern Lincolnshire and Goole Hospitals NHS Foundation Trust, Cliff Gardens, DN15 7BH, United Kingdom.

E-mail address: preetihg@hotmail.com (P. Gandhi).

<http://dx.doi.org/10.1016/j.gmit.2016.10.003>

2213-3070/Copyright © 2017, The Asia-Pacific Association for Gynecologic Endoscopy and Minimally Invasive Therapy. Published by Elsevier Taiwan LLC. This is an open access article under the CC BY-NC-ND license (<http://creativecommons.org/licenses/by-nc-nd/4.0/>).

Please cite this article in press as: Limbachia D, Gandhi P, Laparoscopic retrieval of a foreign body (broken surgical knife) from retroperitoneal space: An interesting case, Gynecology and Minimally Invasive Therapy (2017), <http://dx.doi.org/10.1016/j.gmit.2016.10.003>

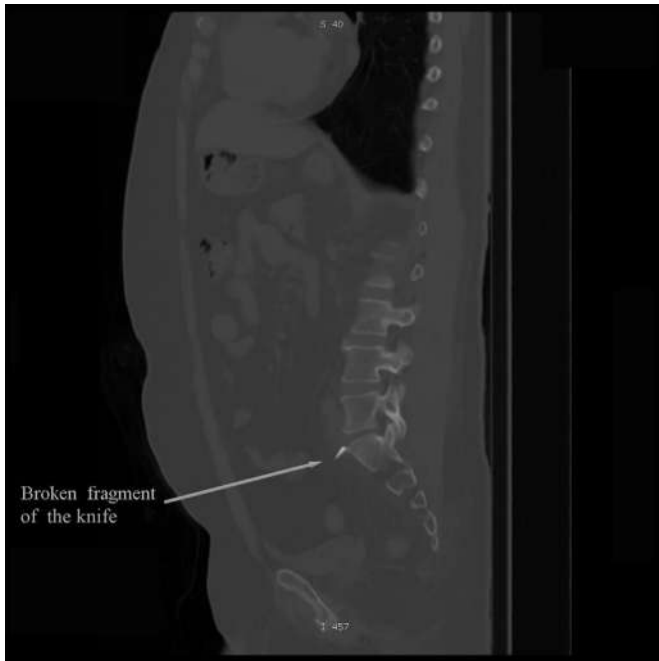


Figure 1. X-ray showing broken piece of knife.

knife firmly and the surgeon ensured the tissues surrounding the fragment were pushed down gently, with the help of Maryland and bipolar graspers to facilitate its removal. The assistant then gradually pulled out the knife fragment, which was successfully extracted via the 5-mm port on the left side. Operation time was 40 minutes and the postoperative course was uneventful.

Supplementary data related to this article can be found at <http://dx.doi.org/10.1016/j.gmit.2016.10.003>.

Discussion

Breakage of the surgical knife is a risk associated with spinal surgery.¹ Retrieval could be challenging, particularly if the broken knife fragment migrates anteriorly and gets embedded in the retroperitoneal space. It carries a potential risk of visceral and

vascular injury.^{1,2} Traditionally, an open anterior approach is used in cases of retained broken blade fragment after unsuccessful attempts to remove it during the initial surgery.¹ Our case report demonstrates that a laparoscopic approach is an alternative to remove the sharp foreign body from the retroperitoneal space. To our knowledge this is the first case in the literature where a broken knife fragment has been removed laparoscopically from the retroperitoneal space by a gynecology endoscopist. On reviewing the literature, there has been a report of removal of foreign body (air gun bullet in a child) 0.5 cm from the vena cava³ and another case report of retrieval of translocated intrauterine device from the retroperitoneum via laparoscopic approach.⁴

Our case is unique as the surgical knife has sharp edges with a high risk of injury to the major blood vessels in the retroperitoneal space. Laparoscopy gave us the advantage of better visualization, and coupled with layer-wise meticulous dissection, controlled movements with adequate traction and retraction helped to manage this challenging task effectively. Advanced laparoscopic skills are required by the surgeon to operate in retroperitoneal space and undertake dissection over the major blood vessels in order to achieve good outcomes and minimize complications. The knowledge of the anatomy of the retroperitoneal space, holy plane of dissection along with methodical, and systematic approach is fundamental for the procedure to be successful. Laparoscopic intervention in our case of retrieving a broken knife from the retroperitoneal space, demonstrates expanding horizons of minimal invasive surgery. It is a safe and effective approach to deal with complex and challenging situations. This is a rare case that gynecology endoscopists may not encounter; however, this report could prove to be very useful information to manage similar cases in the future for removal of any foreign body from the retroperitoneal space.

References

1. Rahimizadeha A, Haddadib K. Is transforaminal retrieval of intradiscal deeply seated broken surgical knife blade all time pars sparing? *A case report. Int J Surg Case Rep.* 2016;19:131–133.
2. Amirjamshidi A, Mehrazin M, Abbassion K. Retained broken knife blade within the disc space. *Spine.* 1994;19:981–984.
3. Murányi M, Józsa T, Benyó M, Salah M, Flaskó T. Laparoscopic removal of a paracaval air gun bullet in a child. *Urol Int.* 2012;89:246–248.
4. Roy KK, Bannerji N, Sinha A. Laparoscopic removal of translocated retroperitoneal IUD. *Int J Gynaecol Obstet.* 2000;71:241–243.